

'Ecstasy' (MDMA)-induced pneumomediastinum and epidural pneumatosis

Hakan Mutlu, Emir Şilit, Zekai Pekkaflı, Mehmet Incedayı, Çınar Başekim, Eşref Kızılkaya

ABSTRACT

Epidural pneumatosis and pneumomediastinum may occur after the inhalation of "Ecstasy" (methylenedioxymetamphetamine), but only one case has been reported in the literature. We report the case of a 21-year-old male patient who presented with epidural pneumatosis and pneumomediastinum. Chest CT demonstrated the pneumomediastinum and multiple air bubbles within the spinal canal.

Key words: • mediastinal emphysema • substance-related disorders

An amphetamine derivative called methylenedioxymethamphetamine (MDMA) is illegally sold in the streets under the popular name 'Ecstasy'. Its effects resemble both amphetamines and hallucinogens. It is sold in the form of tablets with elephant, bird, etc. illustrations stamped on. It is also named as "white doves" and shows its effect within 20-60 minutes in the form of liveliness, vivaciousness, being at ease with the opposite sex, self-confidence, and changes in body temperature and perception. Although 'Ecstasy' is mostly taken orally, some people inhale it through nose or smoke it. Since the use of amphetamine or amphetamine-containing drugs at low doses for weight control has caused side effects like addiction and mental disorders, it has been drawn from the application field for this purpose. Today, amphetamines are used rarely in hyperactive children and in cases like narcolepsy. This drug can cause subarachnoid hemorrhage, brain infarcts, and trembling through its toxic and stimulant effect on the central nervous system. Side effects like increase in blood pressure and pulse, dehydration, pupillary narrowing, sweating, and inability to enjoy anything without using 'Ecstasy' are also seen. Heart, kidney, and liver failure, and coordination problems can be encountered. 'Ecstasy' is strictly contraindicated for patients having asthma, depression, or epilepsy. Sudden death can occur in individuals taking 'Ecstasy' which can be attributed to dehydration, increase in body temperature, or lack of knowledge about the actual nature of the substance taken. Abstinence is in the form of a sense of emptiness, fatigue, headache, and dizziness (1).

Case report

A 21-year-old male who fell down after taking 'Ecstasy' was admitted to the emergency room with shortness of breath and sudden onset of chest pain. He had alcohol addiction in his medical history which was treated with benzodiazepines. There was swelling in the neck and subcutaneous crepitation in physical examination. Laboratory findings were normal. Pneumomediastinum and subcutaneous emphysema were present in postero-anterior chest X-ray. Computed tomography (CT) of the chest revealed mediastinal, subcutaneous, and epidural pneumatosis (Figure).

Discussion

Pneumomediastinum caused by amphetamines has been previously reported (2). Pneumomediastinum is a situation related to occurrences like seizures, asthma, and positive pressure ventilation in general. Pneumomediastinum following the intake of inhalation drugs has also been reported previously. Initially, alveolar tearing occurs causing pulmonary interstitial emphysema. This tearing can be due to various mechanisms causing transmural pressure differences (3). On the other hand, vomit-

From the Department of Radiology (H.M. ✉ hmutlu@hpasa.gata.edu.tr), Gülhane Military Academy of Medicine, Haydarpaşa Research and Training Hospital, Istanbul, Turkey.

Received 21 November 2003; revision requested 30 January 2004; revision received 19 February 2004; accepted 27 June 2004.

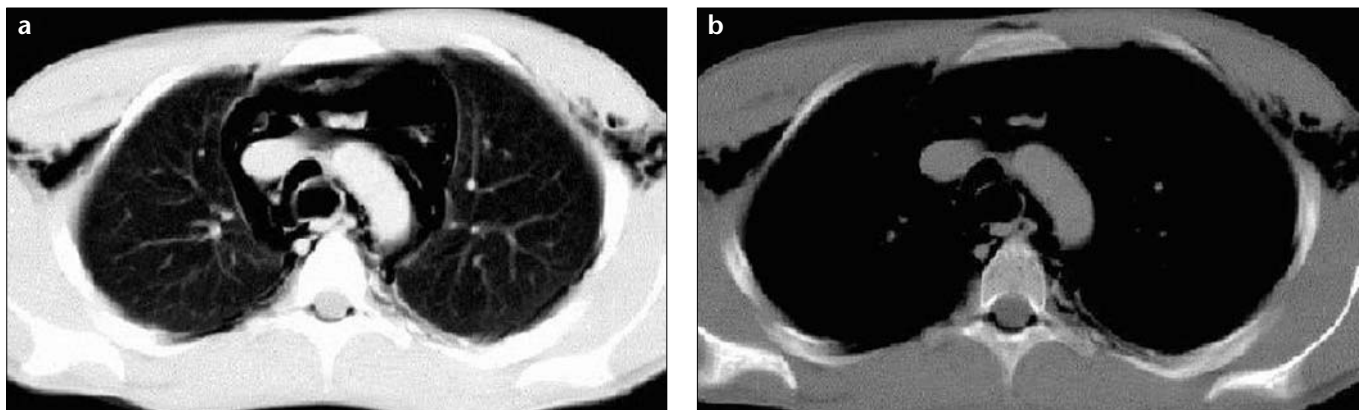


Figure. a, b. Transverse pre-contrast CT images at the arcus aorta level demonstrates pneumomediastinum and epidural pneumatosis on parenchymal (a) and mediastinal (b) window settings.

ing caused by the Valsalva maneuver applied in order to increase the euphoric feeling and high levels of physical activity also increase the alveolar pressure temporarily (2, 4, 5). As a result, air entering the pulmonary interstitial space passes to the mediastinum through leakage via bronchovascular layers.

Epidural pneumatosis is the presence of air in the epidural space which can be seen in various situations like trauma, epidural anesthesia, lumbar puncture, pneumothorax, epidural abscess, or pneumomediastinum. Epidural pneumatosis together with pneumomediastinum has been previously reported (4), and the history of inhalation of 'Ecstasy' was present in only one case (6). When air is present in the mediastinum, it can leak through the neural foramina of the intercostal nerves since there are no fascial restrictions between the posterior mediastinum and epidural space. Typically, air enters into the epidural space from the posterior aspect due to relatively lower resistance in the loose

connective tissue compared to that in the rich vascular network anteriorly. Epidural air related to pneumomediastinum is a benign situation and no further investigation and treatment are necessary (4, 7).

'Ecstasy' is widely used in Europe and the United States to release the mental stress of the young people, to increase the sexual activity, and to supply the energy needed by those who dance till morning in nightclubs. Although the prevalence in Turkey is not known exactly, complications of 'Ecstasy' have been reported before (7). 'Ecstasy' usage among high school and medical students in Turkey is known to have an increasing trend (8, 9).

'Ecstasy' use in the world and in Turkey is increasing, and complications due to its use are increasing in parallel. Therefore, being alert to its complications is necessary. Epidural pneumatosis related to 'Ecstasy' and accompanying spontaneous pneumomediastinum formation are rare but possible occurrences.

References

1. Cole JC, Sumnall HR. Altered states: the clinical effects of Ecstasy. *Pharmacol Ther* 2003; 98:35-58.
2. Mazur S, Hitchcock T. Spontaneous pneumomediastinum, pneumothorax and ecstasy abuse. *Emerg Med* 2001; 13:121-123.
3. Seaman ME. Barotrauma related to inhalational drug abuse. *J Emerg Med* 1990; 8:141-149.
4. Hazouard E, Koninck J C, Attucci S, et al. Pneumothorax and pneumomediastinum caused by repeated Müller's maneuvers: complications of marijuana smoking. *Ann Emerg Med* 2001; 38:694-697.
5. Goldberg RE, Lipuma JP, Cohen AM. Pneumomediastinum associated with cocaine abuse: a case report and review of the literature. *J Thorac Imaging* 1987; 2:88-89.
6. Bernaerts A, Verniest T, Vanhoenacker F et al. Pneumomediastinum and epidural pneumatosis after inhalation of "Ecstasy" *Eur Radiol* 2003; 13(3):642-643.
7. Aribas OK, Gormus N, Aydogdu KD. Epidural emphysema associated with primary spontaneous pneumothorax. *Eur J Cardiothorac Surg* 2001; 20 (3):645-646.
8. Corapcioglu A, Ogel K. Factors associated with Ecstasy use in Turkish students. *Addiction* 2004; 99:67-76.
9. Akvardar Y, Demiral Y, Ergor G, et al. Substance use in a sample of Turkish medical students. *Drug Alcohol Depend* 2003; 24;72(2):117-121.